Isolated Ocular Motor Nerve Palsies

Nathan H. Kung, MD[1] Gregory P. Van Stavern, MD[2]

[1] Department of Neurology, Washington University in St. Louis, St. Louis, Missouri
[2] Department of Ophthalmology, Washington University in St. Louis, St. Louis, Missouri

Address for correspondence Gregory P. Van Stavern, MD, Department of Ophthalmology and Visual Sciences, Washington University in St. Louis, 660 South Euclid Avenue, Campus Box 8096, Saint Louis, Missouri, 63110 (e-mail: VanStavernG@vision.wustl.edu).

Semin Neurol 2015;35:539–548.

Abstract

An isolated ocular motor nerve palsy is defined as dysfunction of a single ocular motor nerve (oculomotor, trochlear, or abducens) with no associated or localizing neurologic signs or symptoms. When occurring in patients aged 50 or older, the most common cause is microvascular ischemia, but serious etiologies such as aneurysm, malignancy, and giant cell arteritis should always be considered. In this article, the authors review the clinical approach, anatomy, and differential diagnosis of each isolated ocular motor nerve palsy and discuss the clinical characteristics, pathophysiology, and treatment of microvascular ischemia.

Keywords
- ocular motility
- diplopia
- microvascular ischemia

The approach to the adult patient aged 50 years and older with an isolated ocular motor nerve palsy begins with a thorough assessment of the patient's history and neuro-ophthalmic examination. The goal is localization to the specific dysfunctional nerve and generation of a differential diagnosis. In this context, "isolated" means a single ocular motor nerve (oculomotor, trochlear, or abducens) is affected and there are no associated or localizing neurologic signs or symptoms. Following the accurate identification of the involved nerve, one can then use the best available evidence to determine the yield of neuroimaging and other ancillary testing in ruling out structural or other malignant causes of isolated palsies. If the cause is determined to be microvascular, then the focus turns to identification of associated risk factors, the likelihood of improvement, and the use of patching, prisms, or surgical strategies to correct residual diplopia. We will discuss each of these steps and review the approach to each of the isolated ocular motor nerve palsies.

Approach to Diplopia and Localization

Binocular diplopia due to ocular misalignment may occur due to lesions of the supranuclear, internuclear, nuclear, intramedullary fascicular, or extramedullary formed portions of a cranial nerve. Once the cranial nerve reaches its target, a disorder of the neuromuscular junction or extraocular muscle itself may also cause diplopia. Accordingly, the approach to the adult patient with the new onset of diplopia begins with a thorough assessment of the history and neuro-ophthalmic examination.[1–5] The important questions in assessing diplopia include whether it is monocular or binocular; whether the diplopia is primarily horizontal, torsional, or vertical; in which direction of gaze the diplopia is maximal; whether there is any fatigability or diurnal variation in the severity of the diplopia; whether there is any associated ptosis or facial muscle weakness; whether it is constant or intermittent; and whether there are any other localizing symptoms such as involvement of other cranial nerves, limb weakness, ataxia, proptosis, or impairment in visual acuity or color perception (see ►**Table 1**). The abrupt onset of sustained diplopia is more suggestive of a microvascular event than progressive or chronic intermittent diplopia. As a general rule, all patients over the age of 50 years should also be assessed for signs and symptoms of giant cell arteritis, which can occasionally present with diplopia.[6]

The most important initial question in evaluating double vision is to determine whether it is monocular or binocular in etiology. Ask the patient whether the symptom resolves by closing *either* eye. If closing either eye resolves the abnormality, this indicates misalignment of the eyes (strabismus). If closing only one particular eye resolves the diplopia, this suggests an ocular problem isolated to the affected eye such as refractive error or ocular surface disease.

Issue Theme Neuro-Ophthalmology; Guest Editor: Beau B. Bruce, MD, PhD

Copyright © 2015 by Thieme Medical Publishers, Inc., 333 Seventh Avenue, New York, NY 10001, USA. Tel: +1(212) 584-4662.

DOI http://dx.doi.org/10.1055/s-0035-1563568.
ISSN 0271-8235.

Downloaded by: IP-Proxy Washington University at St. Louis, Washington University. Copyrighted material.

Table 1 Diplopia: Historical clues to etiology

Monocular or binocular
Horizontal, vertical, or torsional
Gaze direction of maximal diplopia
Fatigability or diurnal variation
Presence of ptosis or facial weakness
Constant or episodic
Presence of any other neurologic symptoms

Binocular diplopia should be further characterized as horizontal, suggesting sixth nerve involvement (lateral recti); vertical, suggesting third or fourth nerve involvement (vertical recti and obliques); or predominantly torsional, suggesting fourth involvement (superior oblique). If a patient can identify the direction of gaze with maximal diplopia, knowledge of the yoked eye muscles in each cardinal direction of gaze can help to identify the affected muscle and nerve (see ►**Fig. 1**). Horizontal diplopia worse in right gaze suggests weakness of the right lateral rectus or left medial rectus, whereas horizontal diplopia worse in left gaze suggests weakness of the left lateral rectus or right medial rectus. A unilateral weakness of eye movement should help determine which muscle is affected. Notably, each eye should be tested independently to remove pseudorestrictive effects related to alternating monocular fixation and vergence when both eyes are open.

When red flag symptoms other than diplopia are prominent, common mimics of isolated ocular motor nerve palsies should be considered (see ►**Table 2**). The presence of fatigability, ptosis, facial weakness, proximal weakness, and diurnal variation with symptoms worse late in the day suggests myasthenia gravis. The presence of proptosis, periorbital edema, and diurnal variation with symptoms early in the morning suggests thyroid eye disease, which can occur even in the clinically euthyroid state.[7] The presence of afferent visual impairment with optic nerve involvement suggests an orbital apex syndrome.[8] The gradual onset of episodic diplopia with longstanding transient diplopia and head tilt suggests decreasing fusional reserve and decompensated congenital strabismus.[2]

In hospitalized patients, the concurrent onset of ophthalmoplegia with altered mental status, ataxia, and nystagmus suggests thiamine deficiency, which may occur in alcoholics, malnourished patients, and other at-risk patient populations.[9] A similar picture could be seen with anticonvulsant intoxication.[10] The combination of areflexia, bulbar weakness, and diplopia suggests Miller-Fisher syndrome, a subtype of Guillain-Barré syndrome.[11] Wound or foodborne botulism

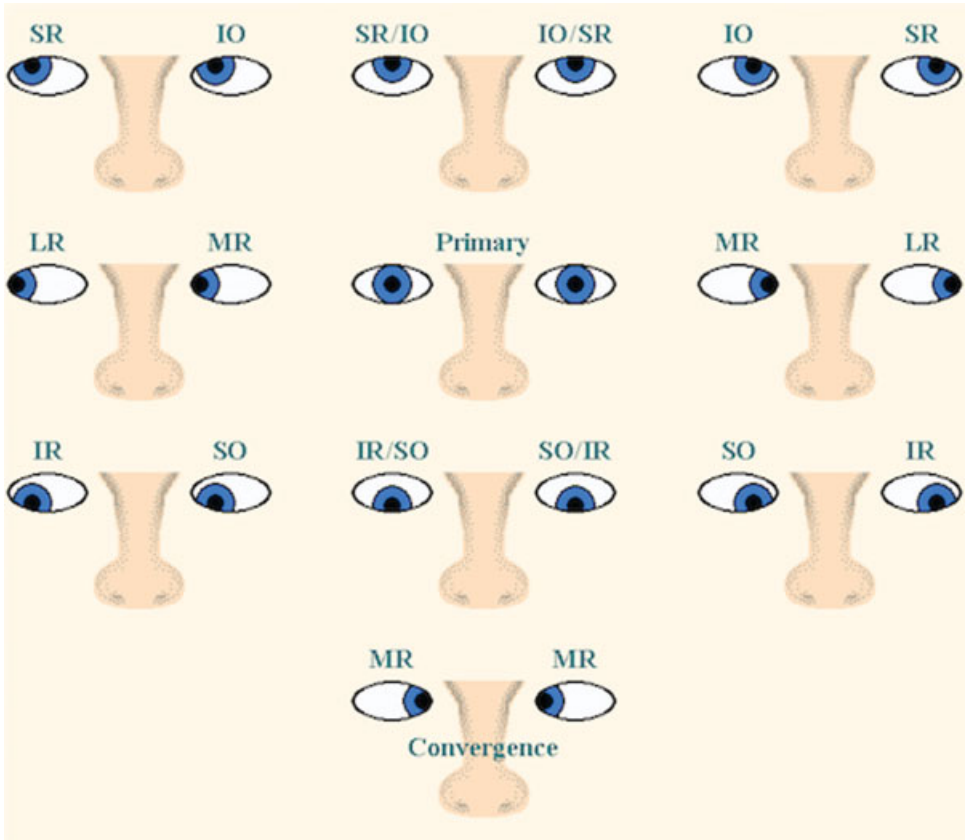

Fig. 1 Yoked muscles in each cardinal direction of gaze. SR, superior rectus; IO, inferior oblique; IR, inferior rectus; LR, lateral rectus; MR, medial rectus. Available at: http://www.tedmontgomery.com/the_eye/eom.html. Accessed March 23, 2015. (Reprinted with permission from Ted Montgomery.)

Downloaded by: IP-Proxy Washington University at St. Louis, Washington University. Copyrighted material.

Table 2 Diplopia "red flags": Clues to a nonmicrovascular etiology

Ptosis, fatigability, facial weakness
Proptosis, periorbital edema
Afferent visual impairment
Ataxia, ophthalmoplegia
Areflexia, facial weakness
New centrally acting medications

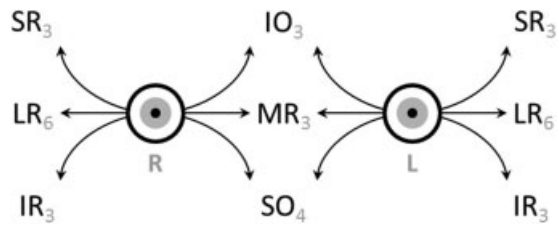

Fig. 2 The primary and secondary actions of each extraocular muscle. SR, superior rectus; IO, inferior oblique; IR, inferior rectus; LR, lateral rectus; MR, medial rectus.

should be considered in adults with diplopia and descending weakness.[12] Other less common causes of diplopia such as Friedrich ataxia, Kearns-Sayre syndrome, Wilson disease, Whipple disease, or other metabolic conditions should also be considered.[13]

Anatomy of the Ocular Motor Nerves

The oculomotor nerve innervates the superior rectus, inferior rectus, medial rectus, and inferior oblique. The trochlear nerve innervates the superior oblique, and the abducens nerve innervates the lateral rectus. The primary and secondary actions of each muscle are depicted in ►**Fig. 2** and described in ►**Table 3**. Of note, *in-cyclotorsion* describes rotation of the superior pole of each eye toward the nose, whereas *ex-cyclotorsion* describes rotation of the superior pole toward the lateral canthus.

The third nerve nuclei are situated in the upper midbrain at the level of the superior colliculus, near the vertical midline, just anterior to the cerebral aqueduct. Each levator palpebrae is supplied by one unpaired midline nucleus, but each ocular muscle supplied by the third nerve has a paired subnucleus on each side of the midline. The exception is the medial rectus, which has three subnuclei on each side. The axons arising from each subnucleus (collectively known as the third nerve fascicle) then travel ipsilaterally in a topographic distribution through the anterior portions of the midbrain, passing through the red nucleus and cerebral peduncle, to form the third nerve within the subarachnoid space. The exception is the superior rectus subnucleus, which sends its axons contralaterally through the opposite superior rectus subnucleus before joining that contralateral third nerve fascicle going through the anterior midbrain into the subarachnoid space. Once in the subarachnoid space, the third nerve passes between the superior cerebellar and posterior cerebral arteries and travels anteriorly near the posterior communicating artery and uncus of the ipsilateral temporal lobe. It then pierces the dura and travels in the ipsilateral cavernous sinus on its way to the superior orbital fissure, where the nerve fibers enter the orbit and meet their respective target muscles within the region of the orbital apex.[14–17]

The fourth nerve nucleus is situated in the lower midbrain at the level of the inferior colliculus, near the midline, just anterior to the cerebral aqueduct. There is one nucleus on each side, corresponding to the cell bodies of the neurons comprising each trochlear nerve. In contrast to the third nerve fascicles, which course anteriorly, the fourth nerve fascicles course posteriorly around the cerebral aqueduct and cross the midline posteriorly to emerge from the brainstem contralaterally just past the vertical midline. The subarachnoid segment of the trochlear nerve then courses around the midbrain and passes anteriorly along the edge of the cerebellar tentorium. When it pierces the dura, it then travels in this contralateral cavernous sinus on its way to the superior orbital fissure, where it meets the superior oblique muscle within the region of the orbital apex.[14–17]

The sixth nerve nucleus is situated in the lower pons, near the midline, just anterior to the floor of the fourth ventricle. There is one nucleus on each side, corresponding to the cell bodies of the neurons comprising each abducens nerve. Of interest is that the fascicle of the seventh nerve courses just posterior to the nucleus of the sixth nerve, such that it is nearly impossible to lesion the sixth nerve nucleus without causing an ipsilateral seventh nerve palsy.[8] The sixth nerve fascicles course anteriorly through the medial lemniscus and

Table 3 The primary and secondary actions of each extraocular muscle

Nerve	Muscle	Primary action	Secondary action
Oculomotor nerve	Superior rectus	Elevation	In-cyclotorsion
	Inferior rectus	Depression	Ex-cyclotorsion
	Medial rectus	Adduction	
	Inferior oblique	Ex-cyclotorsion	Elevation
Trochlear nerve	Superior oblique	In-cyclotorsion	Depression
Abducent nerve	Lateral rectus	Abduction	

Downloaded by: IP-Proxy Washington University at St. Louis, Washington University. Copyrighted material.

emerge anteriorly at the ipsilateral pontomedullary junction. The nerve then ascends in the subarachnoid space between the pons and clivus and passes anteriorly through Dorello's canal. It then pierces the dura and travels in this ipsilateral cavernous sinus on its way to the superior orbital fissure, where it meets the lateral rectus muscle within the region of the orbital apex.[14–17]

Each ocular motor nerve can be affected anywhere along its course, from the nucleus, to the fascicle, to the nerve in the subarachnoid space, to the nerve in the cavernous sinus, all the way into the orbital apex. When multiple cranial nerves are involved, the localization may be evident based on knowledge of where nerves travel together, or based on other localizing clues. For example, the cavernous sinus contains cranial nerves (CNs) III, IV, VI, V1, V2, and sympathetic autonomic fibers traveling along the carotid artery. The orbital apex contains CNs II, III, IV, VI, V1, as well as the sympathetic autonomic fibers. Diffuse infiltrative processes such as lymphoma or carcinomatosis may involve multiple CNs, including the lower CNs such as VII, IX, X, or XII, within the subarachnoid space on the leptomeningeal surface of the brain. Otorrhea with sixth nerve palsy suggests petrous apicitis, whereas the presence of hemiparesis or ataxia suggests brainstem involvement.[14–17]

When an ocular motor nerve is affected in isolation, however, there are generally few clues to its localization, and neuroimaging may be required to assist in the localization of the injury. Critical factors that inform the need for neuroimaging and contribute to the differential diagnosis include the patient's age, the tempo and duration of onset, the presence or absence of pain, any associated medical conditions, and for third nerve palsy, the status of the pupil.[1]

Evaluation of Oculomotor Nerve Palsy

Physical Examination

Third nerve palsies, when complete or nearly complete, cause the affected eye to adopt a "down-and-out" position due to intact function of the superior oblique and lateral rectus, which tend to depress and abduct the eye. Significant weakness of elevation, depression, and adduction is expected. Many third nerve palsies are "incomplete," with not all innervated muscles affected or less than complete weakness of each affected muscle. Isolated weakness of a single extraocular muscle is rare, however, and suggests an alternate etiology such as myasthenia gravis, thyroid eye disease, local restriction from trauma, or an internuclear ophthalmoplegia.[1] Similarly, isolated pupillary dilation rarely implies third nerve dysfunction, and usually represents tonic pupil, pharmacologic mydriasis, or even benign physiologic anisocoria.[18]

In the setting of adduction weakness from a third nerve palsy, the residual function of the fourth nerve should be assessed by asking the patient to abduct the eye and then depress it, looking carefully at scleral vessels for in-cyclotorsion mediated by the superior oblique.

Etiologies

Oculomotor dysfunction may result from many causes, including microvascular ischemia, aneurysm, head trauma, neoplasm, syphilis, herpes zoster, meningitis, encephalitis, sarcoidosis, vasculitis, lupus, multiple sclerosis, neurosurgical intervention, myelography, influenza, Tolosa-Hunt syndrome, and Paget's disease.[19–21] To provide scope, of the 1,130 retrospective cases of third nerve palsy reported by the Mayo clinic from the 1950s to the 1980s for patients of all age groups, 270 were due to undetermined causes, 225 were due to microvascular ischemia, 179 were due to aneurysm, 166 were due to head trauma, 141 were due to neoplasm, and 149 were due to other causes.[22] It should be noted that these cases were not evaluated by modern neuroimaging techniques; however, so small compressive lesions may have been missed. This same limitation applies to the retrospective series of fourth and sixth nerve palsies from the Mayo clinic described in later sections of this review.

Many of the above causes of third nerve palsy will have overt systemic manifestations with additional signs and symptoms.[23] When occurring in clinical isolation in adults 50 years of age and older, however, microvascular ischemia and aneurysm comprise a majority of cases and therefore warrant special discussion.[24–26]

The third cranial nerve is unique due to its association with the urgent, potentially life-threatening complication of an enlarging aneurysm, classically of the posterior communicating artery. Fibers mediating pupillary constriction course along the outer portions of the nerve and thus suggest impingement when affected.[17] Therefore, patients with third nerve palsy and any degree of pupillary involvement require urgent vascular imaging of the head to rule out an expanding aneurysm, though approximately one-third of patients with microvascular ischemia may also have some involvement of the pupil. In these cases, however, the degree of anisocoria is typically < 1 mm, and the pupil remains reactive.[27,28]

Patients with preserved pupillary function may still be at risk of harboring an aneurysm if they have incomplete paresis of the innervated extraocular muscles or if the ptosis is not complete because the third nerve palsy may still be in progression.[29] The patients at lowest risk of harboring an aneurysm are those with complete preservation of pupillary function in the setting of complete ptosis, complete paresis of the innervated extraocular muscles, and appropriate vasculopathic risk factors to suggest microvascular ischemia. These patients still require close clinical follow-up, however, to ensure that pupillary involvement does not ensue.[29]

Although the details of the extraocular muscle examinations are not fully reported, two large retrospective series suggest that between 2 to 3% of patients harboring an aneurysm may have no pupillary involvement. Rucker reported a total of 4 out of 114 patients with aneurysmal compression of the third nerve that did not have pupillary involvement.[19,20] Keane reported that only 2 of 143 patients with aneurysmal compression of the third nerve did not have pupillary involvement.[27]

Neuroimaging

Three recent studies have prospectively assessed the yield of urgent neuroimaging in evaluating acute isolated third nerve palsies in patients 50 years of age or older. These three studies performed magnetic resonance imaging (MRI) examinations

Downloaded by: IP-Proxy Washington University at St. Louis, Washington University. Copyrighted material.

on consecutive patients with acute isolated third, fourth, or sixth nerve palsies who presented without trauma, recent neurosurgical intervention, active malignancy, or any other localizing signs and symptoms other than nonspecific headache or pain. The series of third nerve palsy patients are presented here, and the series of fourth and sixth nerve palsy patients are presented under their respective sections.

Chou et al found that 4 of 29 cases of acute isolated third nerve palsy (14%) were due to causes other than microvascular ischemia.[24] Specifically, one was due to neoplasm, one was due to a brainstem infarct, and two were due to aneurysm. All other cases (86%) were determined to be due to microvascular ischemia. Notably, seven of nine patients with pupillary involvement were determined to have microvascular ischemia, with $>$ 2 mm of anisocoria in three of these seven patients. One patient with aneurysm had pupillary sparing with only partial extraocular muscle involvement. Murchison et al found no structural etiologies in 14 consecutive patients with acute isolated third nerve palsy.[25] Tamhankar et al found that 3 of 22 cases (14%) were due to causes other than microvascular ischemia, including pituitary apoplexy and idiopathic enhancement of the third nerve, which later resolved.[26]

Jacobson and Trobe previously explored the risk of harboring an aneurysm in the setting of a negative magnetic resonance angiogram (MRA).[30] In their literature review, they found that most well-documented posterior communicating aneurysms causing third nerve palsies were $\geq$ 5 mm in size rather than $<$ 5 mm in size (91.3% vs. 8.7%). Furthermore, when compared directly with catheter angiography, MRA was able to pick up nearly all aneurysms $\geq$ 5mm in size versus $<$ 5 mm (97% vs. 53.6%). Because the risk of rupture is lower for smaller aneurysms, however, a mathematical interpretation of the data suggests that a properly performed and interpreted MRA will overlook only 1.5% of aneurysms which cause third nerve palsy and that will go on to rupture during the next 8 years if untreated. Clinical follow-up should help to alleviate concerns of an undetected enlarging aneurysm, as affected patients should fail to recover or begin to develop signs of aberrant regeneration.[29] It should be noted that this review was performed before the advent of computed tomography (CT) angiography and higher resolution magnetic resonance (MR) angiography techniques, which likely have greater sensitivity for detecting small aneurysms.

Evaluation of Trochlear Nerve Palsy

Physical Examination

Trochlear nerve palsies result in vertical diplopia with a resting hypertropia (i.e., relative elevation) of the affected eye. Alternate cover testing using prisms remains the gold standard for diagnosing fourth nerve palsies. Prisms are not always readily available, however, and require some expertise to use. When ocular misalignment is mild or not apparent from viewing resting eye positions, vertical diplopia worst when placing the right eye in the down-and-in position suggests involvement of the right superior oblique, whereas vertical diplopia worst when placing the left eye in the down-and-in position suggests involvement of the left superior oblique. Sometimes, the use of a red-colored lens traditionally placed over the right eye can help the patient to distinguish the direction of gaze that gives them the greatest degree of misalignment. The affected eye cannot always reliably be distinguished using this red lens test, however, due to the effects of alternating monocular fixation.

Resolution of diplopia with head tilt away from a hypertropic eye suggests that the diplopia may be the result of a fourth nerve palsy in the higher eye. A left fourth nerve palsy should also show an increased degree of left hypertropia when looking to the right, whereas a right fourth nerve palsy should show an increased degree of right hypertropia when looking to the left.[31,32]

Use of a Maddox rod can help to confirm a fourth nerve palsy by determining ocular cyclotorsion. When holding the Maddox rod with lines oriented in the up-and-down direction, the patient will see a horizontal line in that eye. When held in front of a hypertropic eye, the patient with fourth nerve palsy will see the line as angled downwards nasally (representing ex-cyclotorsion of the eye), whereas the patient with central skew deviation will see the line as angled upwards nasally (representing in-cyclotorsion of the eye).

Etiologies

Trochlear nerve dysfunction has a wide variety of etiologies, including head trauma, malignancy, microvascular ischemia, encephalitis, lupus, herpes zoster, stroke, multiple sclerosis, postviral, and aneurysm.[19–21] To provide scope, of the 578 retrospective cases of fourth nerve palsy reported by the Mayo clinic from the 1950s to the 1980s for patients of all age groups, 186 were due to undetermined causes, 169 were due to head trauma, 103 were due to presumed microvascular ischemia, 28 were due to neoplasm, 5 were due to aneurysm, and 87 were due to other causes, including congenital palsy with decompensation in 79 of these 87 cases.[22] Many of these causes of fourth nerve palsy will have overt systemic manifestations with additional signs and symptoms. When head trauma and congenital causes are excluded, however, most fourth nerve palsies occurring in clinical isolation in adults 50 years of age and older are due to presumed microvascular ischemia.[22,33]

Neuroimaging

In the subsets of patients with acute isolated fourth nerve palsy in the three previously mentioned studies, Chou et al found that only 1 of 14 cases was due to a cause other than microvascular ischemia. Specifically, only one neoplasm was detected. All other cases (93%) were determined to be due to microvascular ischemia.[24] Murchison et al assessed 27 consecutive patients and did not detect any diagnoses other than microvascular ischemia.[25] Tamhankar et al found that 3 of 25 cases (12%) were due to causes other than microvascular ischemia, including one patient with an infarct in the dorsal midbrain.[26]

Evaluation of Abducens Nerve Palsy

Physical Examination

Abducens nerve palsies result in horizontal diplopia and will show a unilateral weakness of abduction in the affected eye. It

Downloaded by: IP-Proxy Washington University at St. Louis, Washington University. Copyrighted material.

is important to test each eye independently because of the pseudo-restrictive effects of alternating monocular fixation and vergence when both eyes are open.

Etiologies

Sixth cranial nerve dysfunction has many causes, including head trauma, malignancy, microvascular ischemia, aneurysm, meningitis, encephalitis, multiple sclerosis, syphilis, poliomyelitis, mastoiditis, cavernous-carotid fistula, idiopathic intracranial hypertension, intracranial hypotension, subarachnoid hemorrhage, intraparenchymal hematoma, and neurosurgical intervention.[19–21] In the retrospective cases of sixth nerve palsy reported by the Mayo clinic from the 1950s to the 1980s for patients of all age groups, 504 were due to an undetermined cause, 413 were due to neoplasm, 287 were due to head trauma, 240 were due to presumed microvascular ischemia, 58 were due to aneurysm, and 417 were due to other causes.[22]

Neuroimaging

Chou et al found that 4 of 23 cases of acute isolated sixth nerve palsy (17%) were due to causes other than microvascular ischemia, including one neoplasm, one brainstem infarct, one new diagnosis of multiple sclerosis, and one case of unexpected pituitary apoplexy.[24] Murchison et al detected only one relevant structural finding, a pontine hemorrhage, in 52 consecutively studied patients (2%). Three incidental findings were noted, however, including a contralateral acoustic neuroma, a contralateral meningioma, and a maxillary sinus tumor.[25] Tamhankar et al determined that 12 of 62 cases (19%) were due to causes other than microvascular ischemia, including one case of cavernous sinus B cell lymphoma, one case of petroclival meningioma, and three cases of GCA diagnosed on the basis of an elevated erythrocyte sedimentation rate (ESR), elevated C-reactive protein (CRP), and positive temporal artery biopsies.[26]

In one additional study of patients with acute isolated sixth nerve palsy, Bendszus et al prospectively assessed 43 consecutive patients aged 2 to 82 years and found a causative lesion in 63% of patients.[34] The median age of the study group was 48 years, however, younger than in the three previously mentioned prospective neuroimaging studies that only evaluated patients aged 50 years and older.

Neuroimaging Recommendations

Given the above recent prospective data and unique disease associations of each particular cranial nerve palsy, a reasonable conservative approach would be to follow the guidelines previously proposed by Murchison et al.[25] Patients should receive an MRI in the setting of an acute isolated third, fourth, or sixth cranial nerve palsy if any of the following criteria are met: (1) age $<$ 50 years, (2) found to have a pupil-involving or any pupil-sparing partial third nerve palsy, (3) known to have a history of cancer of any type at any time, or (4) found to have any other concerning or localizing neurologic signs or symptoms (see ►**Table 4**).

Table 4 Neuroimaging recommendations

Magnetic resonance brain and orbits with and without gadolinium:
If aged $<$ 50 years
If found to have pupil-involving or pupil-sparing partial third nerve palsy
If known to have cancer of any type at any time
If any other localizing signs or symptoms
If not improved by 1 month
If not resolved by 3 months

A wider approach to neuroimaging with MRI/MRA performed on all or nearly all patients presenting with acute isolated third, fourth, and sixth nerve palsies is also reasonable if the resources are available and both the physician and patient desire a more expeditious and definitive initial evaluation.[35] A referral to a neuro-ophthalmologist could also be considered to screen for subtle motility deficits that might implicate another ocular motor nerve or suggest an alternate diagnosis. With all ocular motor nerve palsies, MRI is the preferred neuroimaging modality. Fat-saturated orbital imaging should also be included, as this sequence will allow better evaluation of the cavernous sinus and intraorbital portions of the ocular motor nerves.

Once the neuroimaging is performed, it should be personally reviewed; one study found that 38% of patients arriving to an academic neuro-ophthalmology practice with pre-existing neuroimaging had incorrect or suboptimal imaging studies (e.g., CT was performed where MRI was required, or where the image quality was inadequate to definitively rule out a suspected lesion).[36] Studies have also shown that radiologists or observers without specific training in neuroradiology may miss relevant findings on MRI or MRA, especially when the radiologist is given insufficient information to focus on the area of suspected pathology.[37]

If neuroimaging is initially deferred, a lack of resolution by 3 months, or failure to demonstrate any recovery by one month, should prompt further investigations including neuroimaging.[35] Of note, there have been several reported cases of spontaneously remitting sixth nerve palsies in the setting of skull base tumors, however, thereby emphasizing the need to take all clinical factors into account when determining the need for neuroimaging.[38]

High-Resolution Neuroimaging Techniques

Many clinical studies of the yield of neuroimaging, including several of the studies previously discussed, have relied on the use of traditional MRI techniques and sequences to evaluate for tumors, aneurysms, and strokes, largely considered to be the most worrisome structural abnormalities in the setting of a cranial nerve palsy. However, more recent high-resolution three-dimensional (3D) sequences, including constructive interference in the steady state (CISS), fast imaging employing

Downloaded by: IP-Proxy Washington University at St. Louis, Washington University. Copyrighted material.

steady-state acquisition (FIESTA), turbo-spin-echo with variable flip angle (SPACE), and balanced turbo field echo (BTFE) are now able to reliably visualize the entire course of the ocular motor nerves from their exit in the brainstem all the way through to the superior orbital fissure and into the orbital apex.[39–41] Each segment can then be studied in detail, including the cisternal, dural, interdural (cavernous), foraminal, and extraforaminal portions of the nerve. The spatial resolution of these techniques can reach 0.6 mm or better, and even the smallest nerves such as the fourth and sixth can often be visualized (see ►**Fig. 3**).[42,43]

The course of the third nerve is readily visualized on these sequences. For example, using 0.6-mm slices, 3D-CISS can demonstrate the exact relationship of the third nerve to the posterior communicating and superior cerebellar arteries in the setting of an aneurysm[39]; 3D-CISS can also reveal the precise anatomy of the cavernous sinus and show the relationship of each nerve to local masses or the internal carotid artery.[44] With postcontrast high-resolution sequences, idiopathic inflammation and enhancement of the nerves might also be better visualized, such as in Tolosa-Hunt syndrome[39] or in recurrent ophthalmoplegic cranial neuropathies.[45] Although adding to the time and complexity of MRI examinations, these sequences demonstrate the increasing capacity of technology to aid our understanding of otherwise cryptogenic or "idiopathic" ocular motor nerve palsies.

Characteristics of Microvascular Ischemia

The diagnosis of microvascular ischemia is often presumptive and clinically based, as there is no known laboratory or imaging correlate. Although a general consensus exists in the literature about the features that a microvascular palsy should exhibit, there are no formalized diagnostic criteria for this disorder.[46] Furthermore, the certainty of the diagnosis cannot be fully determined at the initial presentation. Rather, the diagnosis is fully realized when the patient's clinical history and course conform over time to the expected natural history of a microvascular palsy. Signs and symptoms of multiple cranial neuropathy, myasthenia gravis, thyroid eye disease, head trauma, congenital nerve palsy, giant cell arteritis, multiple sclerosis, syphilis, and Lyme disease should remain absent at follow-up.[47]

Microvascular palsies are thought to occur most often in adults 50 years of age or older[48] with existing vascular risk factors such as hypertension,[48–50] hyperlipidemia,[50] diabetes,[47,49,50] left ventricular hypertrophy,[47] and smoking.[51] The onset should be acute to subacute, but when examined early in the course of their illness, patients may show progression in ophthalmoparesis for a period of 2 to 4 weeks.[52–54] Systemic symptoms are typically absent, but up to two-thirds of patients may report pain, typically in the ipsilateral brow, which may occur before, during, or after the onset of diplopia.[26,52,55]

Following a period of relative stability, the patient's diplopia should then begin to resolve, with recovery expected in 70% or more of cases,[21,22,51] typically within a period of approximately 3 months.[52–54] In clinical practice, failure to completely recover in a reasonable timeframe (<3 to 6 months) should raise concern for an alternate etiology.

Recurrence of microvascular palsies has been reported. In one long-term retrospective review of 59 patients with

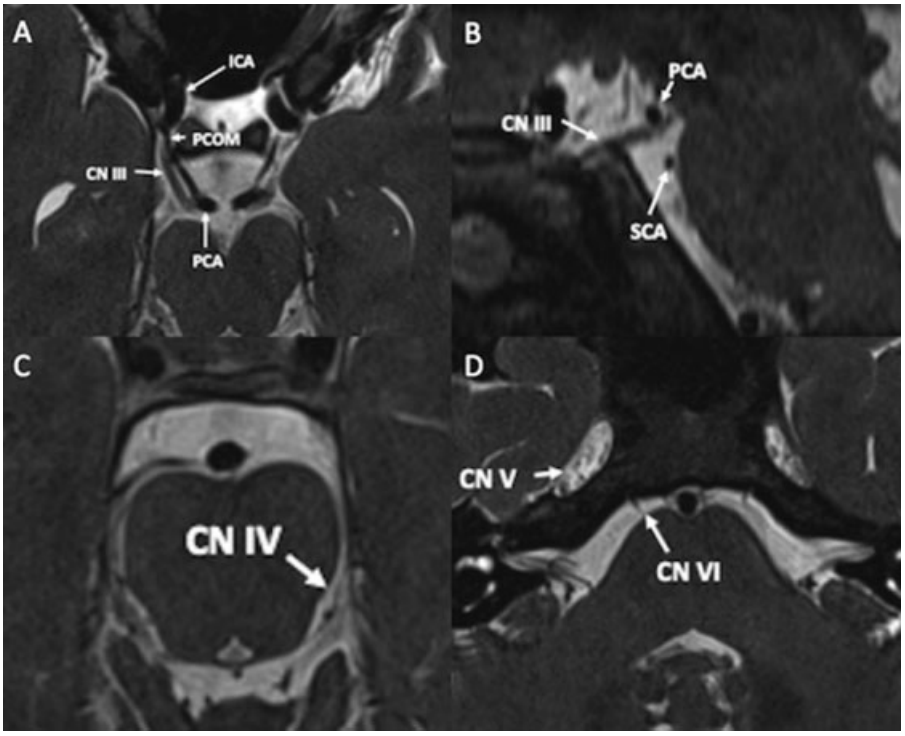

Fig. 3 High-resolution imaging of (**A**) the oculomotor nerve in the subarachnoid space, (**B**) the oculomotor nerve as it courses near the posterior cerebral artery and superior cerebellar artery, (**C**) the trochlear nerve in the subarachnoid space, and (**D**) the abducens nerve as it exits the brainstem. CN, cranial nerve; SCA, superior cerebellar artery; PCA, posterior cerebellar artery.

Downloaded by: IP-Proxy Washington University at St. Louis, Washington University. Copyrighted material.

microvascular sixth nerve palsy, 16 patients (31%) experienced 24 recurrent events either in the same or contralateral eye. Most patients experienced only one recurrence, but three patients had two recurrences and one patient had four recurrences.[51] Using a different methodology, Keane found that 26 ocular motor nerve palsies had previously occurred within his cohort of 141 patients with acute diabetic third nerve palsy.[27]

Pathology of Microvascular Ischemia

Little is known about the actual pathophysiology of microvascular ocular motor nerve palsies, presumably because the disease is inherently self-limited and not life-threatening. Accordingly, few patients have been examined at autopsy.

In 1957, Dreyfus et al[56] reported a 62-year-old diabetic woman with acute left third nerve palsy who expired due to an enlarging neck hematoma following an open left carotid arteriogram to rule out aneurysm. At autopsy, microscopic sections from the intracavernous portion of the left oculomotor nerve revealed areas of extensive myelin loss and fragmentation of the remaining nerve sheaths. Examination of the vasa nervorum revealed thickening and hyalinization of the blood vessels, suggestive of chronic vascular changes. No local vascular occlusions were noted. Although the most prominent changes were found in the nerve sheath myelin, fragmented axon particles were also noted in local macrophages.

In 1970, Asbury et al[57] reported an 88-year-old woman with a history of prior right-sided microvascular third nerve palsy who developed a left-sided microvascular third nerve palsy one month prior to her death from congestive heart failure. On her autopsy, the most prominent finding was a focal zone of demyelination with preserved underlying axons located in the second quarter of the intracavernous segment of the left third nerve. Notably, the area of demyelination appeared to lie in a watershed vascular zone between which branches from the anterior and posterior circulation met and supplied the third nerve. Arterial hyalinization was observed in the vasa nervorum, suggestive of chronic vascular change.

Weber et al[58] reported in 1970 an autopsy on a third patient with a history of presumed diabetic oculomotor palsy 5 months prior to death. Similar to the above cases, the patient was found to have a segment of the third nerve with a significant reduction in myelin staining with lesser injury to the underlying axons. In contrast to prior cases, this lesion was found in the subarachnoid portion of the nerve rather than in the intracavernous portion of the nerve. Analysis of the vasa nervorum showed hyaline thickening.

Interestingly, although an etiology for the ipsilateral brow pain typically associated with microvascular palsies was not discovered in the above autopsy series, anatomical studies in other mammals have revealed trigeminal sensory fibers that travel through the substance of the oculomotor nerve.[59]

Treatment of Microvascular Ischemia

There have been no treatment trials evaluating interventions directed toward hastening or improving the recovery of microvascular nerve palsies. As previously mentioned, spontaneous recovery is expected in 70% or more of cases of microvascular ischemia,[21,22,51] typically within a period of 3 months.[47,52–54] Therefore, the treatment of microvascular ischemia largely centers on the use of patching, prisms, and strabismus surgery to relieve the patient's diplopia.[60]

Only one study has evaluated the effect of aspirin in the setting of an ischemic nerve palsy. This retrospective case-control study found that a similar proportion of patients with microvascular nerve palsies were already taking aspirin compared with a group of age- and gender-matched controls, suggesting that aspirin use was not fully protective against having a microvascular palsy.[61]

For patients in the acute period of their illness, patching or fogging of one eye with handmade or commercial solutions is typically the most cost-effective and reasonable initial option. In fact, patients may arrive in the office with self-constructed patches, having discovered the binocular nature of their diplopia.

Monocular occlusion with a patch is a simple method of preventing diplopia. Occasionally, an occlusive (black) contact lens can be used to allow for peripheral vision while blocking central diplopia. In children under the age of 6, sustained patching can result in amblyopia, and such management should be done in conjunction with a pediatric ophthalmologist.[62,63] Adult patients can safely patch either eye without concern for amblyopia. Another common concern is the loss of binocular fusion due to monocular patching, but this does not occur with patching for weeks to months. Most patients with central fusion disruption have had severe head trauma[64] or prolonged monocular sensory deprivation for months to years (e.g., dense unilateral cataract[65]). Ocular motility exercises are sometimes also recommended following an ischemic palsy, but there are no clinical data to support motility exercises for this diagnosis.[66]

For patients who require or prefer binocular vision, temporary stick-on prisms can be used over a patient's existing glasses or over clear nonprescription spectacles. Due to the likelihood of spontaneous improvement in ophthalmoparesis over the short term, the least amount of prism that allows the patient to achieve binocular fusion should be used. For patients with both vertical and horizontal components of diplopia, the vertical misalignment should be corrected first, as this axis has the least amount of fusional reserve. Large angles of strabismus are typically not amenable to correction with prism.

Finally, for patients with fixed weakness several months following their ischemic nerve palsy, glasses with ground-in prism correction or strabismus surgery should be considered to help patients minimize residual diplopia.[60] Minimizing diplopia in the straight-ahead and downward positions typically provides the most benefit in the patient's level of function for reading, navigating, and other daily tasks.

Summary

In patients aged 50 years or older, isolated ocular motor nerve palsies are most likely due to microvascular ischemia, but

Downloaded by: IP-Proxy Washington University at St. Louis, Washington University. Copyrighted material.

serious etiologies such as aneurysm and malignancy should be ruled out either with neuroimaging or close clinical follow-up. Giant cell arteritis should always be considered in patients > 50 years of age. The treatment of an ischemic nerve palsy is symptomatic, to relieve the patient's symptoms of diplopia, as no other medical therapies have been proven to be of benefit. Patients who are not known to have vasculopathic risk factors should be examined for hypertension, diabetes, and hyperlipidemia, and those who currently smoke should be advised to quit for general health. Aspirin has not been prospectively studied in patients with ischemic nerve palsies, but may be beneficial for overall health prevention.

Acknowledgments
The authors gratefully acknowledge the assistance of Manu Goyal, MD (Department of Radiology, Washington University in St. Louis, Missouri, USA) in reviewing the radiology discussion and preparing the high-resolution cranial nerve images.

References

1 Friedman DI. Pearls: diplopia. Semin Neurol 2010;30(1):54–65
2 Danchaivijitr C, Kennard C. Diplopia and eye movement disorders. J Neurol Neurosurg Psychiatry 2004;75(Suppl 4):iv24–iv31
3 Pelak VS. Evaluation of diplopia: an anatomic and systemic approach. Hosp Physician 2004;40(3):16–25
4 Brazis PW, Lee AG. Binocular vertical diplopia. Mayo Clin Proc 1998;73(1):55–66
5 Buracchio T, Rucker JC. Pearls and oy-sters of localization in ophthalmoparesis. Neurology 2007;69(24):E35–E40
6 Dasgupta B, Borg FA, Hassan N, et al; BSR and BHPR Standards, Guidelines and Audit Working Group. BSR and BHPR guidelines for the management of giant cell arteritis. Rheumatology (Oxford) 2010;49(8):1594–1597
7 Phelps PO, Williams K. Thyroid eye disease for the primary care physician. Dis Mon 2014;60(6):292–298
8 Azarmina M, Azarmina H. The six syndromes of the sixth cranial nerve. J Ophthalmic Vis Res 2013;8(2):160–171
9 Donnino MW, Vega J, Miller J, Walsh M. Myths and misconceptions of Wernicke's encephalopathy: what every emergency physician should know. Ann Emerg Med 2007;50(6):715–721
10 Praveen-kumar S, Desai M. Ocular motor abnormalities in a patient with phenytoin toxicity—case report and minireview. Clin Neurol Neurosurg 2014;127:116–117
11 Wakerley BR, Uncini A, Yuki N; GBS Classification Group; GBS Classification Group. Guillain-Barré and Miller Fisher syndromes—new diagnostic classification. Nat Rev Neurol 2014;10(9):537–544
12 Centers for Disease Control and Prevention. Botulism. Available at: http://www.cdc.gov/nczved/divisions/dfbmd/diseases/botulism. Accessed March 15, 2015
13 Jordan JT, Samuel G, Vernino S, Muppidi S. Slowly progressive ataxia, neuropathy, and oculomotor dysfunction. Arch Neurol 2012;69(10):1366–1371
14 Prasad S, Volpe NJ. Paralytic strabismus: third, fourth, and sixth nerve palsy. Neurol Clin 2010;28(3):803–833
15 Adams ME, Linn J, Yousry I. Pathology of the ocular motor nerves III, IV, and VI. Neuroimaging Clin N Am 2008;18(2):261–282, x–x
16 Bennett JL, Pelak VS. Palsies of the third, fourth, and sixth cranial nerves. Ophthalmol Clin North Am 2001;14(1):169–185, ix
17 Brazis PW, Masdeu JC, Biller J. Localization in Clinical Neurology. Philadelphia, PA: Lippincott Williams & Wilkins; 2011:173–303
18 Evans RW, Jacobson DM. Transient anisocoria in a migraineur. Headache 2003;43(4):416–418
19 Rucker CW. Paralysis of the third, fourth and sixth cranial nerves. Am J Ophthalmol 1958;46(6):787–794
20 Rucker CW. The causes of paralysis of the third, fourth and sixth cranial nerves. Am J Ophthalmol 1966;61(5 Pt 2):1293–1298
21 Rush JA, Younge BR. Paralysis of cranial nerves III, IV, and VI. Cause and prognosis in 1,000 cases. Arch Ophthalmol 1981;99(1):76–79
22 Richards BW, Jones FR Jr, Younge BR. Causes and prognosis in 4,278 cases of paralysis of the oculomotor, trochlear, and abducens cranial nerves. Am J Ophthalmol 1992;113(5):489–496
23 Bruce BB, Biousse V, Newman NJ. Third nerve palsies. Semin Neurol 2007;27(3):257–268
24 Chou KL, Galetta SL, Liu GT, et al. Acute ocular motor mononeuropathies: prospective study of the roles of neuroimaging and clinical assessment. J Neurol Sci 2004;219(1-2):35–39
25 Murchison AP, Gilbert ME, Savino PJ. Neuroimaging and acute ocular motor mononeuropathies: a prospective study. Arch Ophthalmol 2011;129(3):301–305
26 Tamhankar MA, Biousse V, Ying GS, et al. Isolated third, fourth, and sixth cranial nerve palsies from presumed microvascular versus other causes: a prospective study. Ophthalmology 2013;120(11):2264–2269
27 Keane JR. Third nerve palsy: analysis of 1400 personally-examined inpatients. Can J Neurol Sci 2010;37(5):662–670
28 Jacobson DM. Pupil involvement in patients with diabetes-associated oculomotor nerve palsy. Arch Ophthalmol 1998;116(6):723–727
29 Brazis PW. Isolated palsies of cranial nerves III, IV, and VI. Semin Neurol 2009;29(1):14–28
30 Jacobson DM, Trobe JD. The emerging role of magnetic resonance angiography in the management of patients with third cranial nerve palsy. Am J Ophthalmol 1999;128(1):94–96
31 Parks MM. Isolated cyclovertical muscle palsy. AMA Arch Opthalmol 1958;60(6):1027–1035
32 Zarwell TM, Chou B. Parks three step. In: Eye Dock – A clinical reference for eye care professionals. Available at: http://www.eyedock.com/index.php?option=com_jumi&fileid=5&Itemid=85. Accessed March 20, 2015
33 Keane JR. Fourth nerve palsy: historical review and study of 215 inpatients. Neurology 1993;43(12):2439–2443
34 Bendszus M, Beck A, Koltzenburg M, et al. MRI in isolated sixth nerve palsies. Neuroradiology 2001;43(9):742–745
35 Volpe NJ, Lee AG. Do patients with neurologically isolated ocular motor cranial nerve palsies require prompt neuroimaging? J Neuroophthalmol 2014;34(3):301–305
36 McClelland C, Van Stavern GP, Shepherd JB, Gordon M, Huecker J. Neuroimaging in patients referred to a neuro-ophthalmology service: the rates of appropriateness and concordance in interpretation. Ophthalmology 2012;119(8):1701–1704
37 Elmalem VI, Hudgins PA, Bruce BB, Newman NJ, Biousse V. Underdiagnosis of posterior communicating artery aneurysm in noninvasive brain vascular studies. J Neuroophthalmol 2011;31(2):103–109
38 Volpe NJ, Lessell S. Remitting sixth nerve palsy in skull base tumors. Arch Ophthalmol 1993;111(10):1391–1395
39 Blitz AM, Macedo LL, Chonka ZD, et al. High-resolution CISS MR imaging with and without contrast for evaluation of the upper cranial nerves: segmental anatomy and selected pathologic conditions of the cisternal through extraforaminal segments. Neuroimaging Clin N Am 2014;24(1):17–34
40 Everton KL, Rassner UA, Osborn AG, Harnsberger HR. The oculomotor cistern: anatomy and high-resolution imaging. AJNR Am J Neuroradiol 2008;29(7):1344–1348
41 Seitz J, Held P, Strotzer M, et al. MR imaging of cranial nerve lesions using six different high-resolution T1- and T2(*)-weighted 3D and 2D sequences. Acta Radiol 2002;43(4):349–353

Downloaded by: IP-Proxy Washington University at St. Louis, Washington University. Copyrighted material.

42 Choi BS, Kim JH, Jung C, Hwang JM. High-resolution 3D MR imaging of the trochlear nerve. AJNR Am J Neuroradiol 2010; 31(6):1076–1079
43 Yousry I, Camelio S, Wiesmann M, et al. Detailed magnetic resonance imaging anatomy of the cisternal segment of the abducent nerve: Dorello's canal and neurovascular relationships and landmarks. J Neurosurg 1999;91(2):276–283
44 Yagi A, Sato N, Taketomi A, et al. Normal cranial nerves in the cavernous sinuses: contrast-enhanced three-dimensional constructive interference in the steady state MR imaging. AJNR Am J Neuroradiol 2005;26(4):946–950
45 Gelfand AA, Gelfand JM, Prabakhar P, Goadsby PJ. Ophthalmoplegic "migraine" or recurrent ophthalmoplegic cranial neuropathy: new cases and a systematic review. J Child Neurol 2012;27(6): 759–766
46 Galtrey CM, Schon F, Nitkunan A. Microvascular non-arteritic ocular motor nerve palsies – what we know and how should we treat? Neuroophthalmology 2015;39(1):1–11
47 Jacobson DM, McCanna TD, Layde PM. Risk factors for ischemic ocular motor nerve palsies. Arch Ophthalmol 1994;112(7): 961–966
48 Patel SV, Mutyala S, Leske DA, Hodge DO, Holmes JM. Incidence, associations, and evaluation of sixth nerve palsy using a population-based method. Ophthalmology 2004;111(2): 369–375
49 Patel SV, Holmes JM, Hodge DO, Burke JP. Diabetes and hypertension in isolated sixth nerve palsy: a population-based study. Ophthalmology 2005;112(5):760–763
50 Jung JS, Kim DH. Risk factors and prognosis of isolated ischemic third, fourth, or sixth cranial nerve palsies in the Korean population. J Neuroophthalmol 2015;35(1):37–40
51 Sanders SK, Kawasaki A, Purvin VA. Long-term prognosis in patients with vasculopathic sixth nerve palsy. Am J Ophthalmol 2002;134(1):81–84
52 Capó H, Warren F, Kupersmith MJ. Evolution of oculomotor nerve palsies. J Clin Neuroophthalmol 1992;12(1):21–25
53 Jacobson DM, Broste SK. Early progression of ophthalmoplegia in patients with ischemic oculomotor nerve palsies. Arch Ophthalmol 1995;113(12):1535–1537
54 Jacobson DM. Progressive ophthalmoplegia with acute ischemic abducens nerve palsies. Am J Ophthalmol 1996;122(2):278–279
55 Wilker SC, Rucker JC, Newman NJ, Biousse V, Tomsak RL. Pain in ischaemic ocular motor cranial nerve palsies. Br J Ophthalmol 2009;93(12):1657–1659
56 Dreyfus PM, Hakim S, Adams RD. Diabetic ophthalmoplegia; report of case, with postmortem study and comments on vascular supply of human oculomotor nerve. AMA Arch Neurol Psychiatry 1957;77(4):337–349
57 Asbury AK, Aldredge H, Hershberg R, Fisher CM. Oculomotor palsy in diabetes mellitus: a clinico-pathological study. Brain 1970; 93(3):555–566
58 Weber RB, Daroff RB, Mackey EA. Pathology of oculomotor nerve palsy in diabetics. Neurology 1970;20(8):835–838
59 Bortolami R, D'Alessandro R, Manni E. The origin of pain in 'ischemic-diabetic' third-nerve palsy. Arch Neurol 1993;50(8):795
60 Phillips PH. Treatment of diplopia. Semin Neurol 2007;27(3): 288–298
61 Johnson LN, Stetson SW, Krohel GB, Cipollo CL, Madsen RW. Aspirin use and the prevention of acute ischemic cranial nerve palsy. Am J Ophthalmol 2000;129(3):367–371
62 DeSantis D. Amblyopia. Pediatr Clin North Am 2014;61(3): 505–518
63 Levi DM, Knill DC, Bavelier D. Stereopsis and amblyopia: a mini-review. Vision Res 2015; Jan 29. [ePub ahead of print]
64 Pratt-Johnson JA, Tillson G. Acquired central disruption of fusional amplitude. Ophthalmology 1979;86(12):2140–2142
65 Wylie J, Henderson M, Doyle M, Hickey-Dwyer M. Persistent binocular diplopia following cataract surgery: aetiology and management. Eye (Lond) 1994;8(Pt 5):543–546
66 Rawstron JA, Burley CD, Elder MJ. A systematic review of the applicability and efficacy of eye exercises. J Pediatr Ophthalmol Strabismus 2005;42(2):82–88

Downloaded by: IP-Proxy Washington University at St. Louis, Washington University. Copyrighted material.